

Alfio José Tincani, Antonio Santos Martins  
Albina Altemani, Rui Carlos Scanavini Jr.  
Gilson Barreto, Henriette de Toledo Lage  
João Batista Valério, Giuliano Molina

## Parapharyngeal space tumors: considerations in 26 cases

Head and Neck Service, Department of Surgery, Faculdade de Ciências Médicas,  
Universidade Estadual de Campinas (UNICAMP), Campinas, Brazil

### ABSTRACT

**Context:** Parapharyngeal space tumors comprise less than 0.5% of all head and neck neoplasms.<sup>1</sup> The majority of these tumors are benign, but surgery is usually required to establish the diagnosis and treat the patients. We present 26 patients treated surgically for tumors arising in the parapharyngeal space (PPS) at the State University of Campinas Hospital – UNICAMP.

**Cases Serie:** Of these, 17 (65.5%) had benign and 9 (34.6%) malignant neoplasms. The surgical and pathological data relevant to these cases are highlighted, observing any local recurrence, surgical complications and the five-year survival. Neurogenic tumors and soft tissue sarcomas were, respectively, the most frequent benign (35.3%) and malignant neoplasms (44.5%). Benign tumors accounted for the majority of the cases and involved minimal surgical morbidity with no recurrence during a median follow-up of five years. Malignant tumors had a high rate of recurrence and mortality. Surgery is the treatment of choice for PPS tumors. A knowledge of the anatomy of this site is essential for the safe performance of surgical procedures. Malignant neoplasms have a poor prognosis. Fine needle aspiration was helpful in diagnosis of all tumors.

**Key Words:** Parapharyngeal Space Tumors. Head and Neck Tumors. Parapharyngeal Neoplasms. Head and Neck Surgery.

### INTRODUCTION

Parapharyngeal space (PPS) tumors are rare.<sup>1,2</sup> They comprise less than 0.5% of all head and neck neoplasms.<sup>1</sup> The majority of these tumors are benign, but surgery is usually required to establish the diagnosis and treat the patients. This retrospective review focuses on the histologic distribution of these tumors, the clinical findings and some aspects of anatomy and surgical approaches.

### CASES SERIE

From 1986 to 1996, we submitted 26 patients with PPS tumors to surgery in the State University of Campinas Hospital - UNICAMP. Eighteen (70%) were male with ages varying from 12 to 76 years (median: 53). The surgical approach was dependent on the tumor's pathological type, size and area of invasion into anatomical structures. They were transcervico-submandibular, transcervical, transmandibular and craniofacial. All patients were submitted to complementary diagnosis by imaging and pathological examination.

The presence of a mass in the neck or in the oropharynx (Figure 1) was the most commonly encountered symptom (68%) followed by cervical pain (12%) and dyspnea (4%). In 16% we

observed no specific symptoms. Facial nerve dysfunction was present in 7.5% of the patients, all of them with malignant tumors.

All patients underwent computerized tomography (CT), which correctly located the tumor sites (Figure 2). Angiography was performed in five patients with pulsatile masses (19.2%) and magnetic resonance imaging (MRI) was used in two (7.7%).

As seen in Table 1, benign tumors were most frequently encountered (65.5%). The types were peripheric neurogenic tumor (35.3%), pleomorphic adenoma of the parotid (29.4%), paraganglioma of the carotid body (29.4%) and one case of aneurysm of the internal carotid artery (5.9%). Malignancy was seen in 34.6%. Soft tissue sarcomas accounted for 44.5%, metastatic squamous cell carcinoma 33.3%, and 11.1% were lymphoma and mucoepidermoid carcinoma, both from the parotid gland (Table 2).

Fine needle aspiration (FNA) was performed in 38.5% of all the patients, and correctly provided the diagnosis in 88.9%. Open biopsy was required to define malignancy in 36%. In the rest of them (64%) surgery was performed without previous

pathologic diagnosis, mainly because of the very suggestive diagnostic impression obtained by CT.

The surgical approach to PPS was by the transcervico-submandibular route in 17 cases (65.4%), transcervical in one (3.8%), transmandibular in five (19.2%), and craniofacial in three patients (11.5%). Six patients (23.1%) had radiotherapy in the post-operative period (three with epidermoid carcinoma, two with sarcoma and one with mucoepidermoid carcinoma).

Our results with benign tumors may be considered satisfactory, since we had adequate margins in all of them without early complications, and in a median follow-up of five years no recurrence has occurred. Two patients (7.7%) with neurogenic tumor of the sympathetic chain developed Claude-Bernard-Horner syndrome after the surgery. In five patients (19.2%) with parotid pleomorphic adenoma, there was temporary palsy of the mandibular branch of the facial nerve, which receded about four months after the surgery.

Of the patients with malignant neoplasms, 22% are still alive after a median follow-up of five years. An adequate surgical margin was achieved in only one case (3.8%).

**Table 1 - Pathological Diagnosis. Benign Tumor Type (17/26 - 65.5%)**

Pathologic Diagnosis	n	%
Neurogenic	6	35.3
<i>Vagal</i>	3	
<i>Sympathetic Chain</i>	2	
<i>Cervical Plexus</i>	1	
Paraganglioma (Carotid Body)	5	29.4
Mixed Tumor of the Parotid	5	29.4
Internal Carotid Aneurysm	1	5.9
<b>Total</b>	<b>17</b>	<b>100%</b>

**Table 2 - Pathological Diagnosis. Malignant Tumor Type (9/26 - 34.6%)**

Pathological Diagnosis	n	%
Soft Tissue Sarcoma	4	44.5
Squamous Cell Carcinoma	3	33.3
Mucoepidermoid Carcinoma	1	11.1
Lymphoma	1	11.1
<b>Total</b>	<b>9</b>	<b>100%</b>

## DISCUSSION

Tumors arising in the PPS represent a challenge to the head and neck surgeon. Not only because they are rare, but also because of the wide variety of histological types in this site. Anatomic knowledge is mandatory because of the presence of important structures such as the carotid and jugular vessels and the V, VII, IX, X, XII cranial nerves. Surgery is the mainstay for treatment for these PPS tumors. In our experience there are four types of surgical approach, guided basically by tumor size, histological type and position of the tumor with respect to the major vessels and the styloid process.

The transcervico-submandibular approach provides excellent access to the PPS, allowing dissection of the main trunk of the facial nerve and adequate vascular control. If necessary, the submandibular gland may be removed and the stylomandibular ligament transected for better exposure of the operatory field. We obtained

adequate margins and no major complications occurred during the operations of the benign cases. This approach was extensively used by Myers and Carrau<sup>3</sup> with success.

The transcervical differs from the transcervico-submandibular approach in that the submandibular triangle is not entered.

The transmandibular approach was used for malignant tumors and always as part of a composite resection. Mandibulotomy is performed to achieve adequate exposure. When the mandible was compromised, a segmental mandibulectomy was performed followed by a tracheostomy to avoid respiratory problems during post-operative recovery. The osteosynthesis was performed using a miniplate. We used this approach for all squamous cell carcinomas, for one case of sarcoma and one mucoepidermoid carcinoma.

The infratemporal fossa approach (craniofacial surgery) was used for malignant soft tissue sarcomas (in all cases). The infratemporal fossa must be accessed in an attempt to obtain adequate margins. In this approach, the presence of a neurosurgeon is important so that the structures can be dissected easily.

We agree with Som,<sup>4</sup> who defined the limits of the PPS<sup>5,6</sup> as follows: Superiorly, the temporal bone; medially, the buccopharyngeal fascia that covers the outer aspect of the pharyngeal constrictor muscles; laterally, the fascia on the medial aspect of the masticator space and the fascia over the deep surface of the parotid gland, both of which are formed by the superficial layer of the deep cervical

facia; anteriorly the pterygomandibular raphe; posteriorly, the dorsal layers of the carotid sheath; inferiorly, the styloglossus muscle.

An important practical aspect is the division into pre- and retrostyloid compartments for which the landmark is the tensor veli palatini. The retrostyloid compartment is posterior to this fascia and contains the great vessels, cranial nerves (IX to XII) and lymph nodes. The prestyloid compartment contains the parotid gland and some lymph nodes.

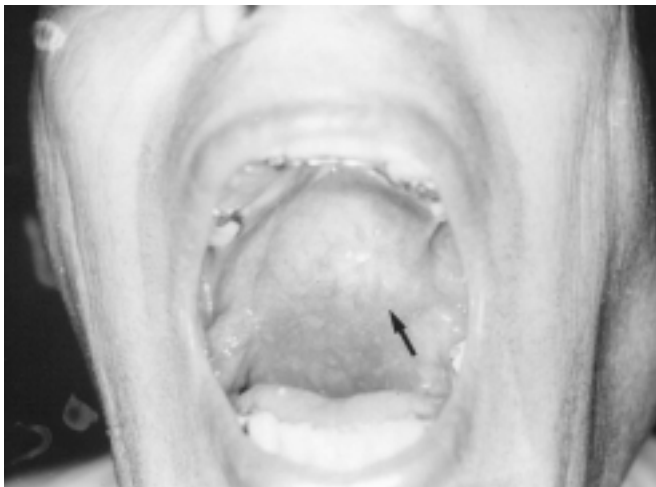Several other large reports<sup>1,3,7-10</sup> found pleomorphic adenoma to be the most common tumor in the PPS, followed by neurogenic tumors and paraganglioma. In our series, neurogenic benign tumors were the most frequent followed by pleomorphic adenoma and carotid body tumors.

Our clinical findings did not differ from other series.<sup>9,11</sup> Pain combined with cranial nerve neuropathy were frequently associated with malignancy (56%).

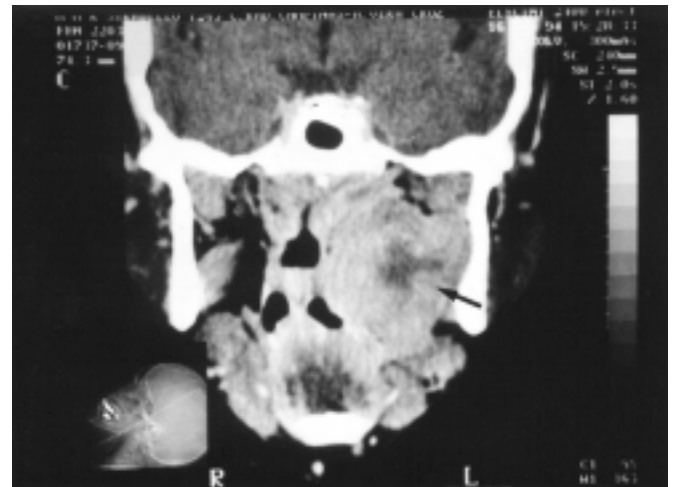
The CT scan was essential in defining diagnosis in most of the cases, and for planning surgical therapy. The advantages of MRI were mainly the sagittal plane view and, in some cases, MRI distinguished the anterior border of the tumors from the surrounding musculature.

Fine needle aspiration (FNA) provided reliable results, especially with benign tumors. All of the soft tissue sarcomas required an open biopsy for correct histological diagnosis and sometimes immunohistochemistry was required.

As mentioned earlier, most tumors were benign and minimal surgical morbidity was



**Figure 1** - Patient with pleomorphic adenoma of parotid gland bulging into the oropharynx (arrow).



**Figure 2** : CT scan in a coronal section, showing the tumor in the parapharyngeal space (arrow).

expected. We followed certain guidelines to avoid iatrogenic complications related to the surgical procedure. First of all, as described earlier, the size of the tumor, its relation to the components of the PPS and the index of suspected malignancy were the main aspects to surgical planning. In addition, we always avoided the transoral approach because its limited operative field increased the rate of vascular complications and the rate of recurrence. We performed angiography on all pulsatile tumors.

Other series<sup>11-13</sup> have also reported poor results with malignant tumors and as in those reports, we also recommend the more aggressive surgical procedures which are feasible with radiotherapy.

Surgery is the treatment of choice for PPS tumors. Imaging examinations and FNA can provide diagnosis in all cases. The transcervico-submandibular approach is better for accessing benign tumors, but when malignancy is present, especially with skull base invasion, the prognosis is poor.

## REFERENCES

- Batsakis JG, Sneign N. Pathology Consultation: Parapharyngeal and retropharyngeal space diseases. *Ann Otol Rhinol Laryngol* 1989;98:320-1.
- Hughes III KV, Olsen KD, McCaffrey TV. Parapharyngeal space neoplasms. *Head Neck Surg* 1995;17:124-8.
- Myers E, Carrau RL. Tumors arising in the parapharyngeal space. *Rev Bras Cir Cab Pesc* 1994;18:1748-55.
- Som PM, Curtin HD. *Head and Neck Imaging*. 3rd Edition. Mosby: 1996;915-51.
- Grodinsky M, Holyoke EA. The facia and facial space of the head, neck and adjacent regions. *Am J Anat* 1938;63:367-408.
- Hollinsead WH. Facia and facial spaces of the head and neck. Chapter 5. In: *Anatomy for Surgeons*. Vol. 1. The Head and Neck. New York, NY: Hoeber-Harper, 1954:282-305.
- Work W, Hybens RH. A study of tumors of the parapharyngeal space. *Laryngoscope* 1974;84:1748-55.
- Smith PG, Sharkey DE. Experience with the resection of the parapharyngeal cancers via the infratemporal fossa approach. *Otolaryngol Head Neck Surg* 1986;94:291-301.
- Carrau RL, Myers EN, Johnson JT. Management of tumors arising in the parapharyngeal space. *Laryngoscope* 1990;100:583-9.
- Warrington G, Emery PJ, Gregory MM, et al. Pleomorphic salivary gland adenoma of the parapharyngeal space. *J Laryngol Otol* 1981;95:205-18.
- Hughes KV, Olsen RD, McCaffrey TV. Parapharyngeal space neoplasms. *Head and Neck* 1995;17(2):124-30.
- Som PM, Biller HF, Lawson W. Tumors of the parapharyngeal space, preoperative evaluation, diagnosis and surgical approaches. *Ann Otol Rhinol Laryngol* 1981;90 (Suppl.8):3-13.
- Carrau RL, Johnson JT, Myers EN. Management of the tumors of the parapharyngeal space. *Head Neck* 1997; 11(5):633-40.

From Head and Neck Service, Department of Surgery, Faculdade de Ciências Médicas, Universidade Estadual de Campinas (UNICAMP), Campinas, Brazil.

## Authors

### Alfio José Tincani

Head of the Head and Neck Service of UNICAMP

### Antonio Santos Martins

Assistant Professor of the Head and Neck Service of UNICAMP

### Albina Altemani

Assistant Professor of Department of Pathology of UNICAMP

### Rui Carlos Scanavini Jr.

Resident of the Head and Neck Service of UNICAMP

### Gilson Barreto

Head and Neck Surgeon – Centro Médico de Campinas Hospital

### Henriette de Toledo Lage

Assistant of the Head and Neck Service of UNICAMP

### João Batista Valério

Resident of the Head and Neck Service of UNICAMP

### Giuliano Molina

Resident of the Head and Neck Service of UNICAMP

**Sources of Funding:** Not declared

**Conflict of interest:** Not declared

**Last received:** 16 July 1998

**Accepted:** 3 August 1998

**Address for correspondence:**

Alfio José Tincani

Rua Prof. Achille Bassi, 140 - casa 6A - Cidade

Universitária Campinas - SP - Brasil - CEP: 13083-530

Email: tincani@turing.unicamp.br

## RESUMO

**Contexto:** Tumores do espaço parafaríngeo compreendendo menos de 0,5% dos tumores de cabeça e pescoço. A maioria destes são benignos, sendo a cirurgia necessária para tratamento e algumas vezes para diagnóstico dos pacientes.

Apresentamos 26 pacientes tratados cirurgicamente no Hospital das Clínicas da UNICAMP por tumores localizados no EPF

**Série de casos:** A média de idade foi de 53 anos, sendo que dos tumores 17 (65,5%) eram benignos e 9 (34,6%)

malignos. Enfatizaremos as técnicas cirúrgicas e dados anatomopatológicos observando ainda as recidivas e sobrevida.

Tumores neurogênicos (35,3%) e sarcomas de partes moles (44,5%) foram os tumores benignos e malignos mais frequentes.

Os tumores benignos apresentaram mínima morbidade cirúrgica e bom prognóstico, inversamente ao ocorrido com os

malignos. A cirurgia é o tratamento de escolha para estes tumores, sendo que os malignos apresentaram pior prognóstico.

Com exames de imagem, punção aspirativa por agulha fina (PAAF) ou biópsia aberta, obtivemos diagnóstico pré-operatório em todos os casos.